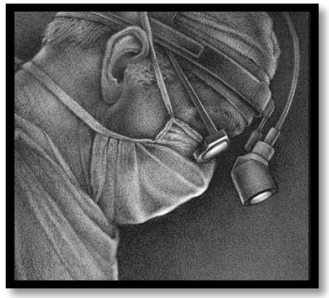

XVIII JORNADAS DE ESPINA BIFIDA

Dr Angel M Hidalgo Ovejero

Jefe de Sº de Cirugia Ortopédica y Traumatologia.

Complejo Hospitalario de Navarra

CONSULTOR CENTRO MEDICIS

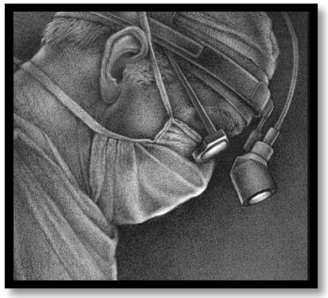

REPRESENTACIONES

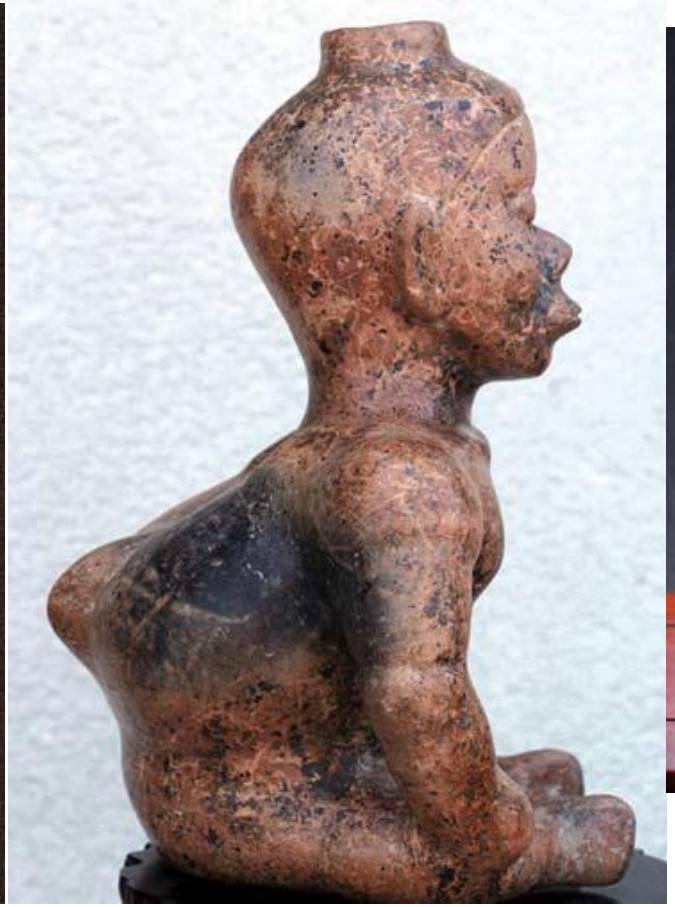



1000 AC PERU

200 AC MEXICO

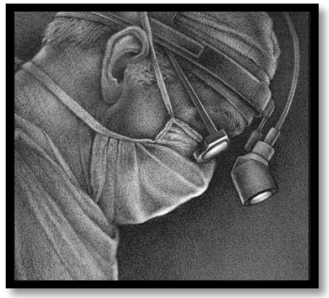

Epidemiologia

- 0,6 / 1000 nacidos vivos.
  - Más frecuentes en varones.

- Hasta un 30 % tienen lesiones ocultas.

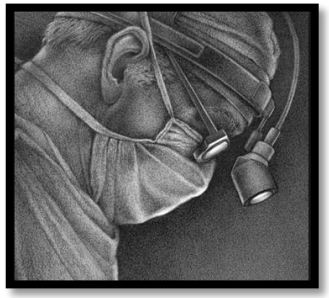

FACTORES DE RIESGO

- Alcohol / Cafeina / Tabaco
- Fiebre.
- Baja ingesta de folatos / metionina / Colina / Vit B12 / Vit C / Zinc
- Dieta de baja calidad.
- Hiperglucemia / Diabetes.
- Obesidad pregestacional.
- Bajo estatus social.
- Estrés.
- Uso de Acido Valproico.
- Contaminantes ambientales / desinfectantes

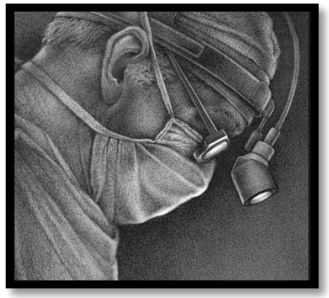

LA COLUMNA EN LA ESPINA BIFIDA

- Lesión inicial:
  - Defecto de cierre de elementos posteriores de la columna, con evisceración en mayor o menor grado de tejido nervioso (1º mes de la concepción).

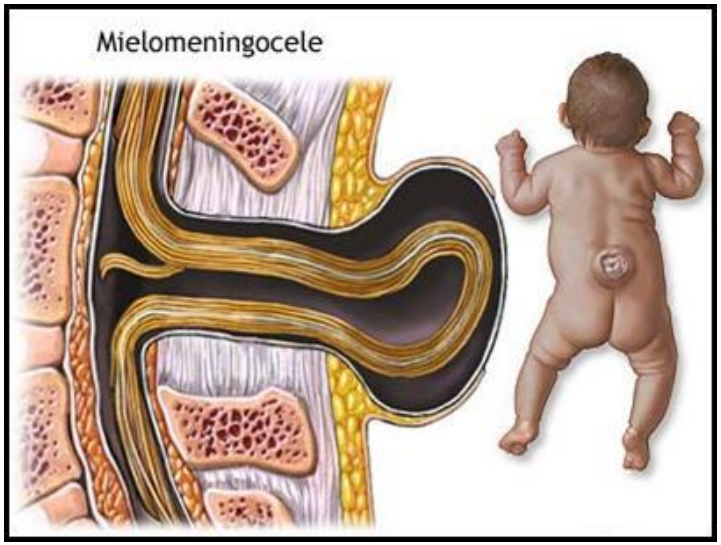

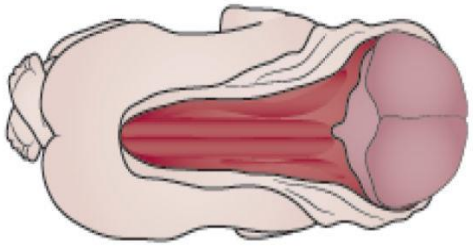

Craniorachischisis
Completely open brain
and spinal cord

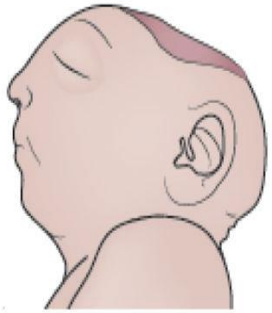

Anencephaly
Open brain and lack
of skull vault

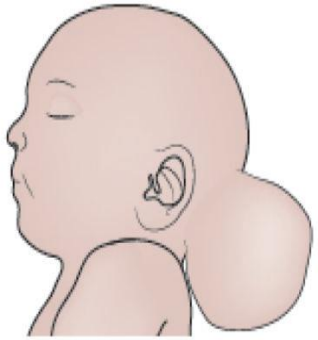

Encephalocele
Herniation of the meninges
(and brain)

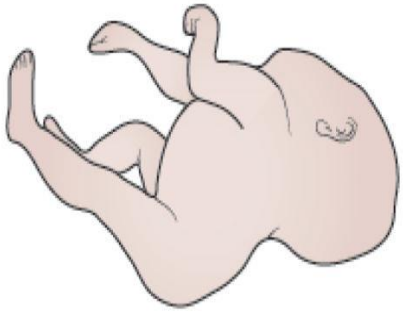

Iniencephaly
Occipital skull and spine defects with
extreme retroflexion of the head

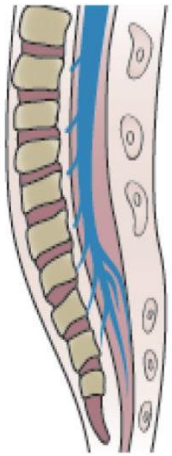

Spina bifida occulta
Closed asymptomatic NTD in which some
of the vertebrae are not completely closed

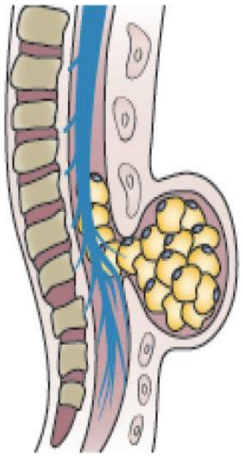

Closed spinal dysraphism
Deficiency of at least two vertebral
arches, here covered with a lipoma

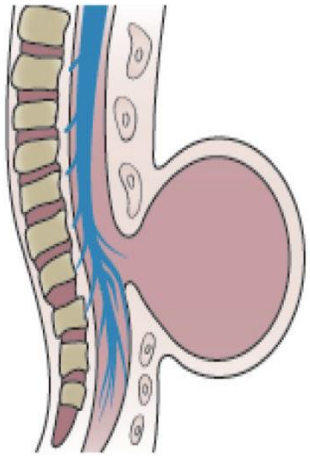

Meningocele
Protrusion of the meninges (filled with CSF)
through a defect in the skull or spine

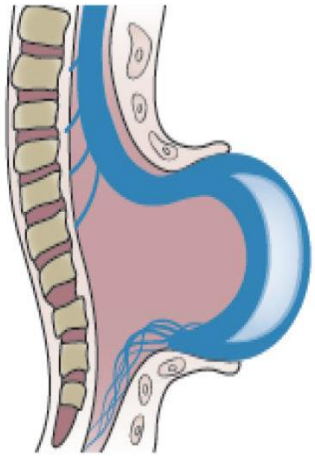

Myelomeningocele
Open spinal cord
(with a meningeal cyst)

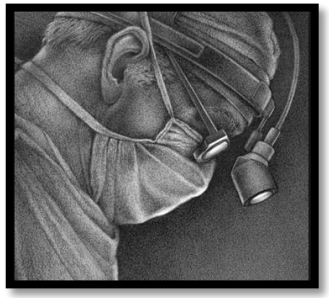

EMBRIOLOGIA

EMBRIOLOGIA

Primary neurulation, days 22 - 26

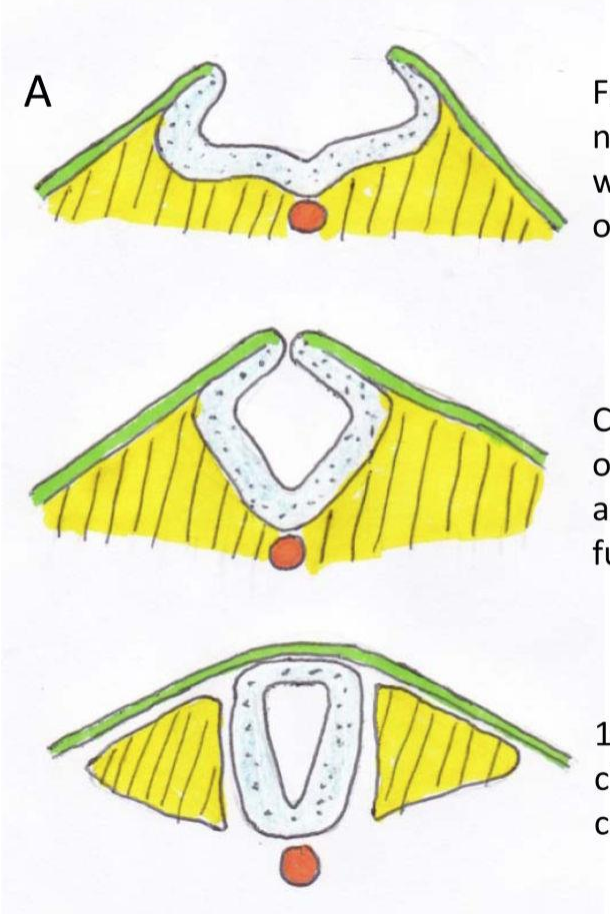

Formation of neural groove with bending of neural plate

Convergence of neural folds and start of fusion

1º neural tube closure complete

Secondary neurulation, days 20 - 40

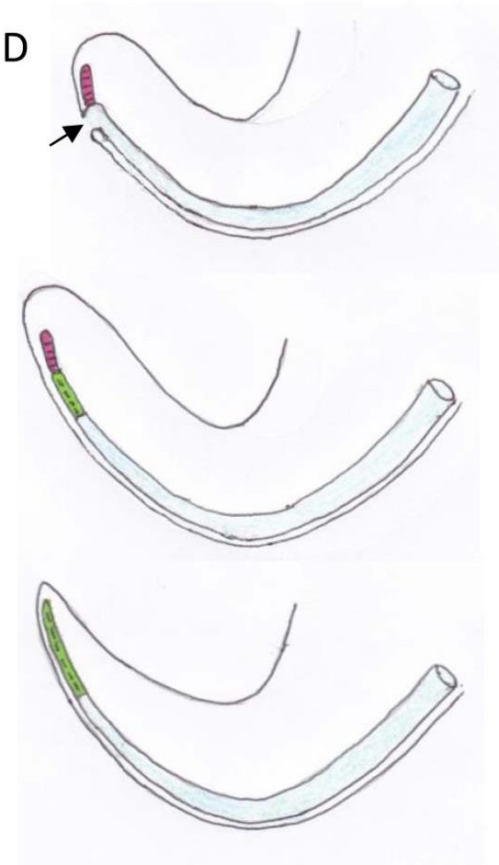

1º neural tube (blue) completed at the caudal neuropore (arrow); medullary cord (red) appears

First formation of 2º neural tube (green) by canalisation of medullary cord

Completion of 2º neurulation prior to regression of the tail

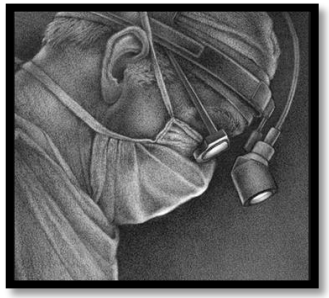

DIAGNOSTICO PRENATAL

ECOGRAFIA

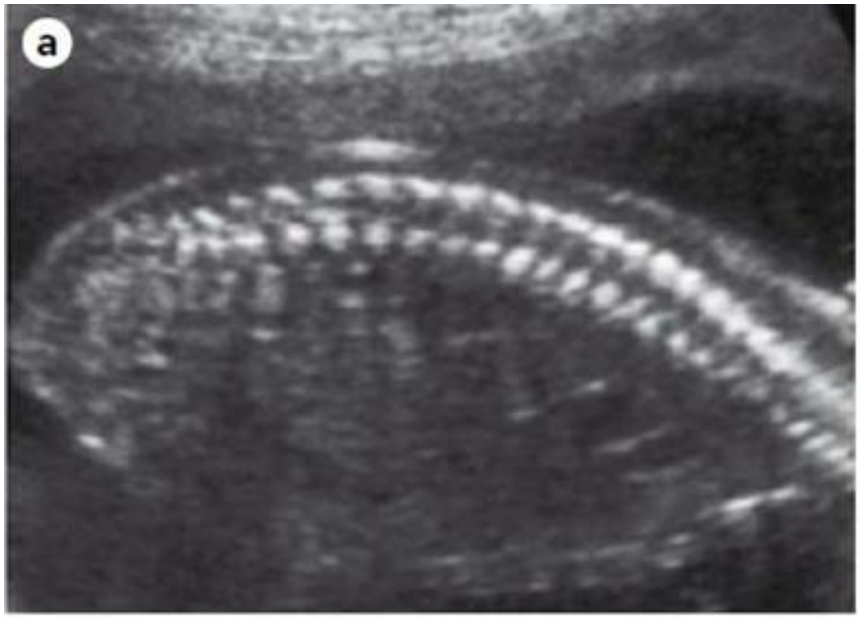

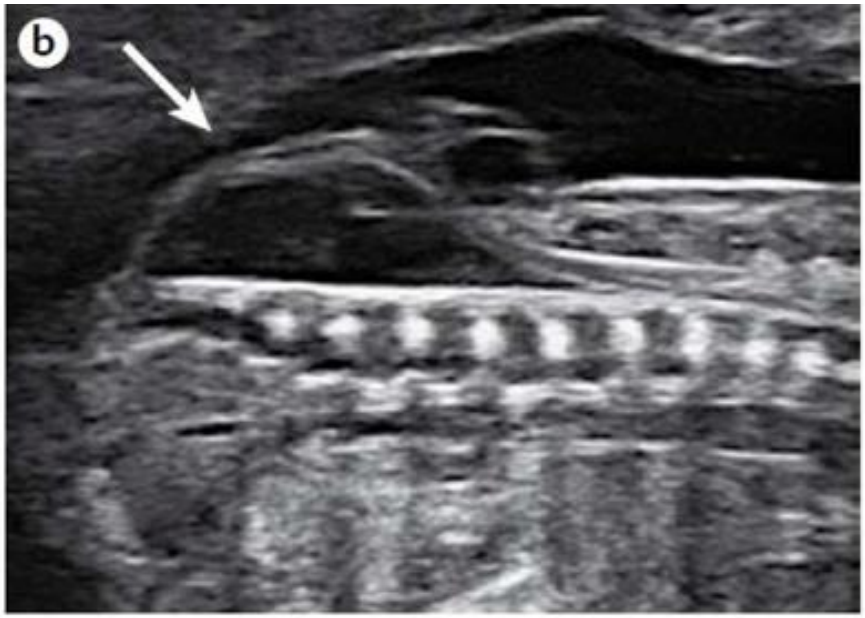

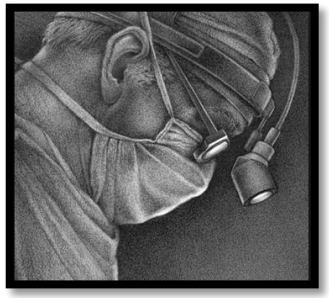

Momento de cierre

- Intraútero (22 Semanas) / Post natal
  - No diferencia en función residual de EEII y esfinteres.
  - Mejor resultado de Chiari e Hidrocefalia cuando se realiza cierre intraútero.

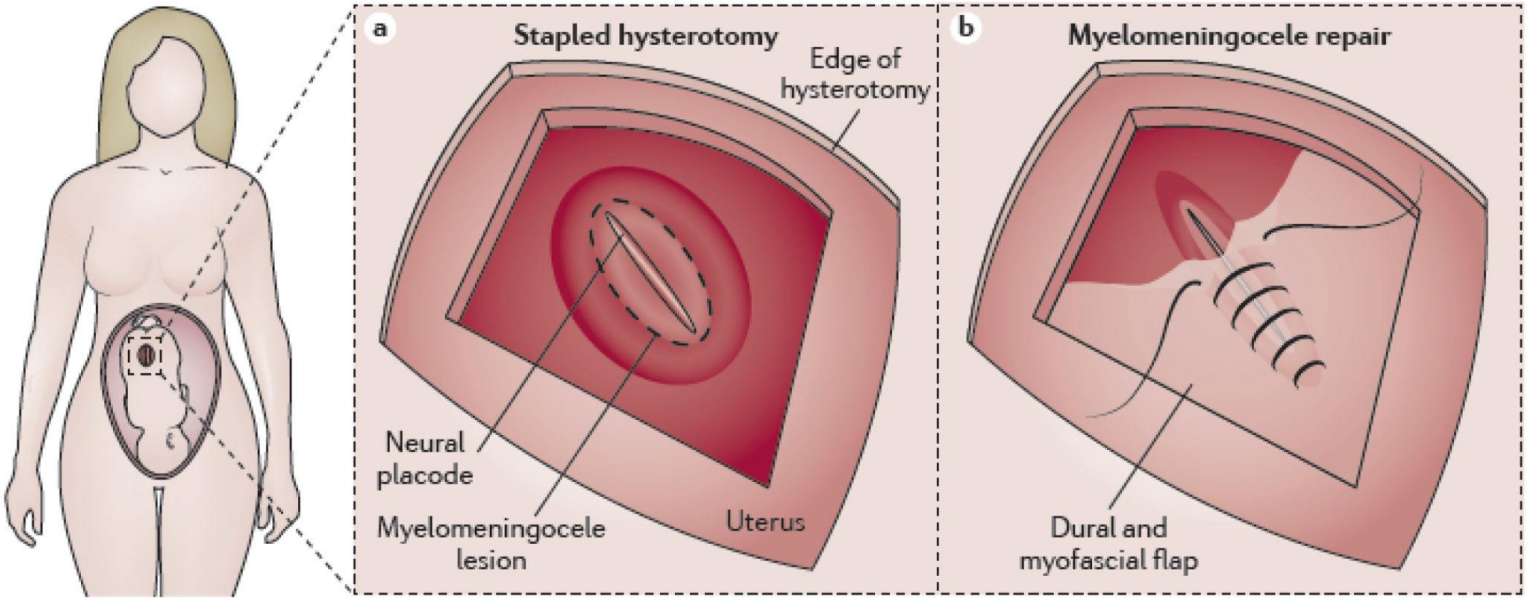

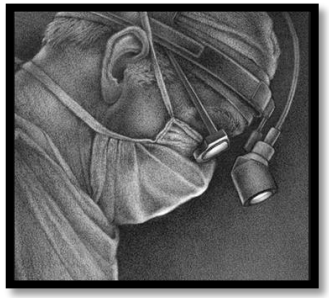

LESIONES ASOCIADAS

- Escoliosis / Cifosis.
- Displasia / luxación de caderas.
- Malformaciones de pies etc

DIFICULTAD PARA LA DEAMBULACION

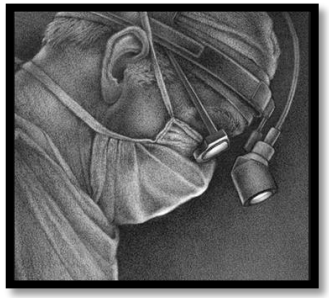

CIFOSIS

- Gibus.
- Escara.
- Problemas de sedestación.
- Alteraciones respiratorias .
- Pérdida de volumen abdominal.

- CORRECCION ALTAMENTE DEMANDANTE

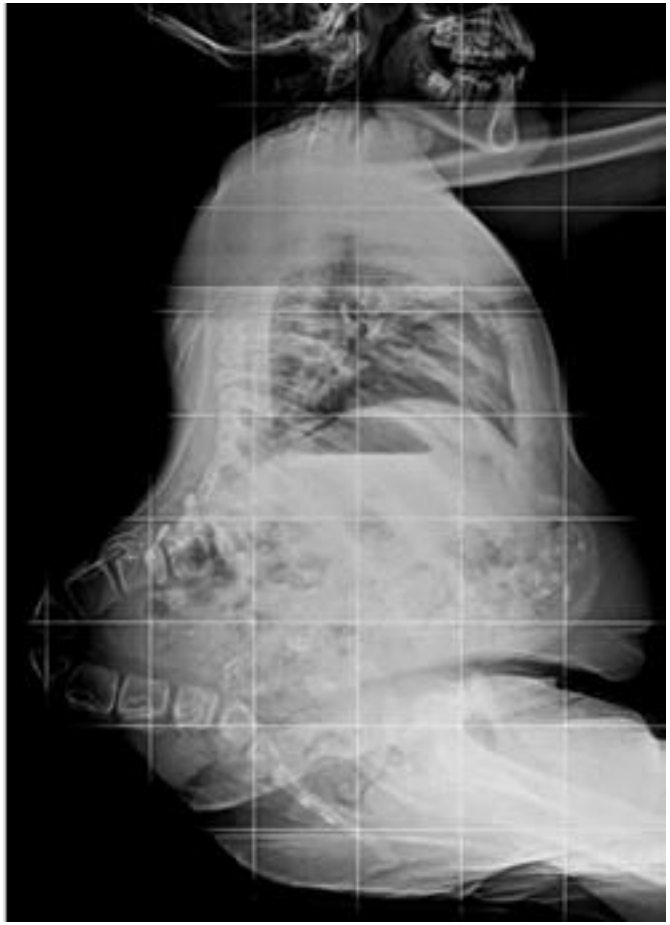

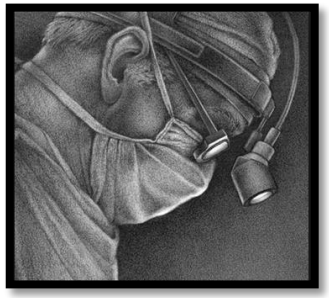

CIFOSIS

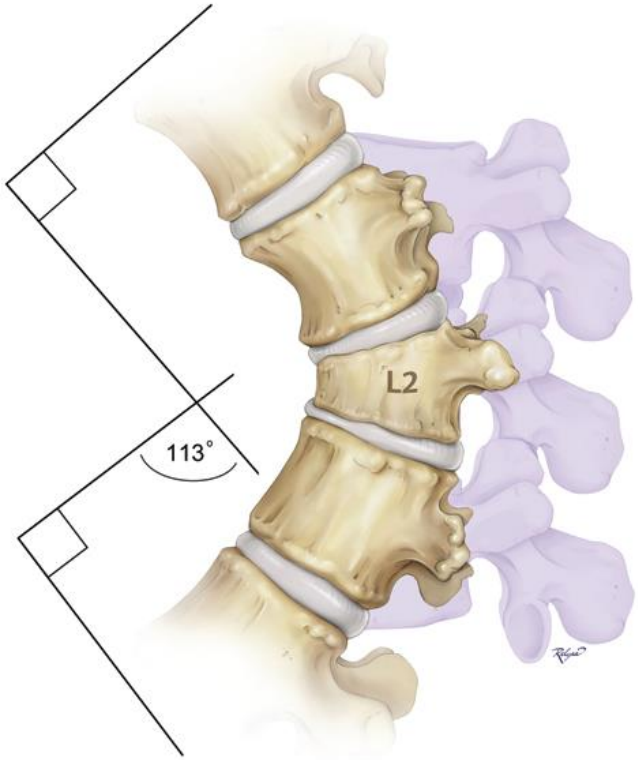

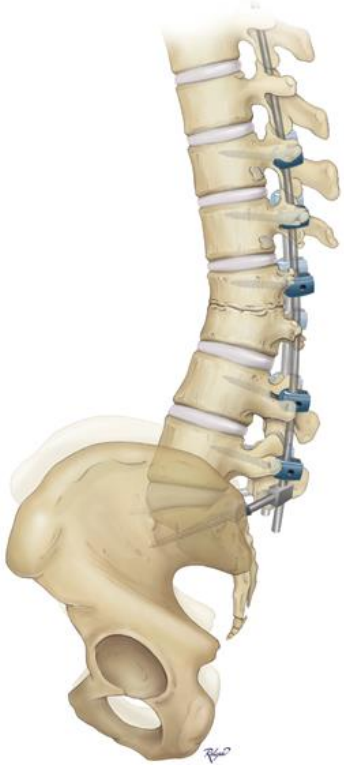

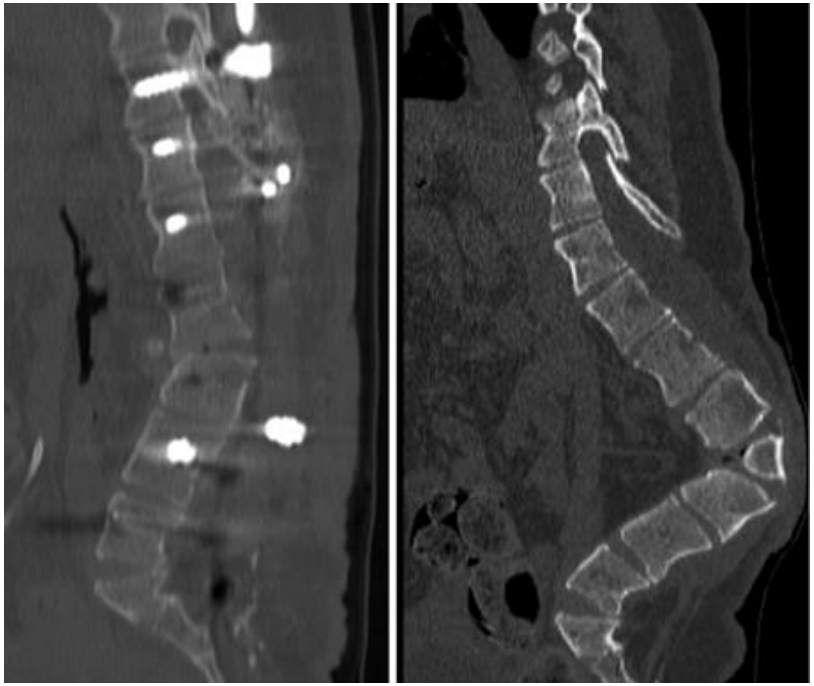

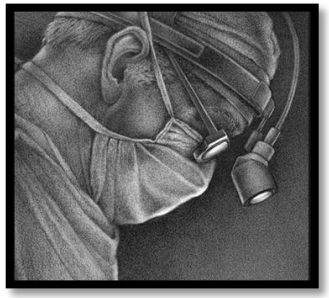

OBJETIVOS DE LA INTERVENCION

- CONSEGUIR UNA CORRECCION ASOCIADA A FUSION:
  - A / P / A-P
  - En columna bien balanceada sobre la pelvis en el plano frontal y lateral.
    - Mantener correcta postura sentada con pelvis horizontal.
    - Evitar problemas de la I. Respiratoria.

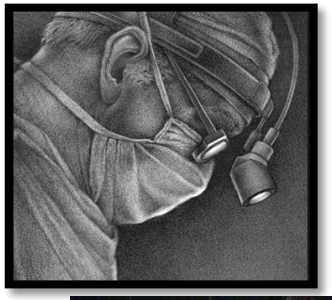

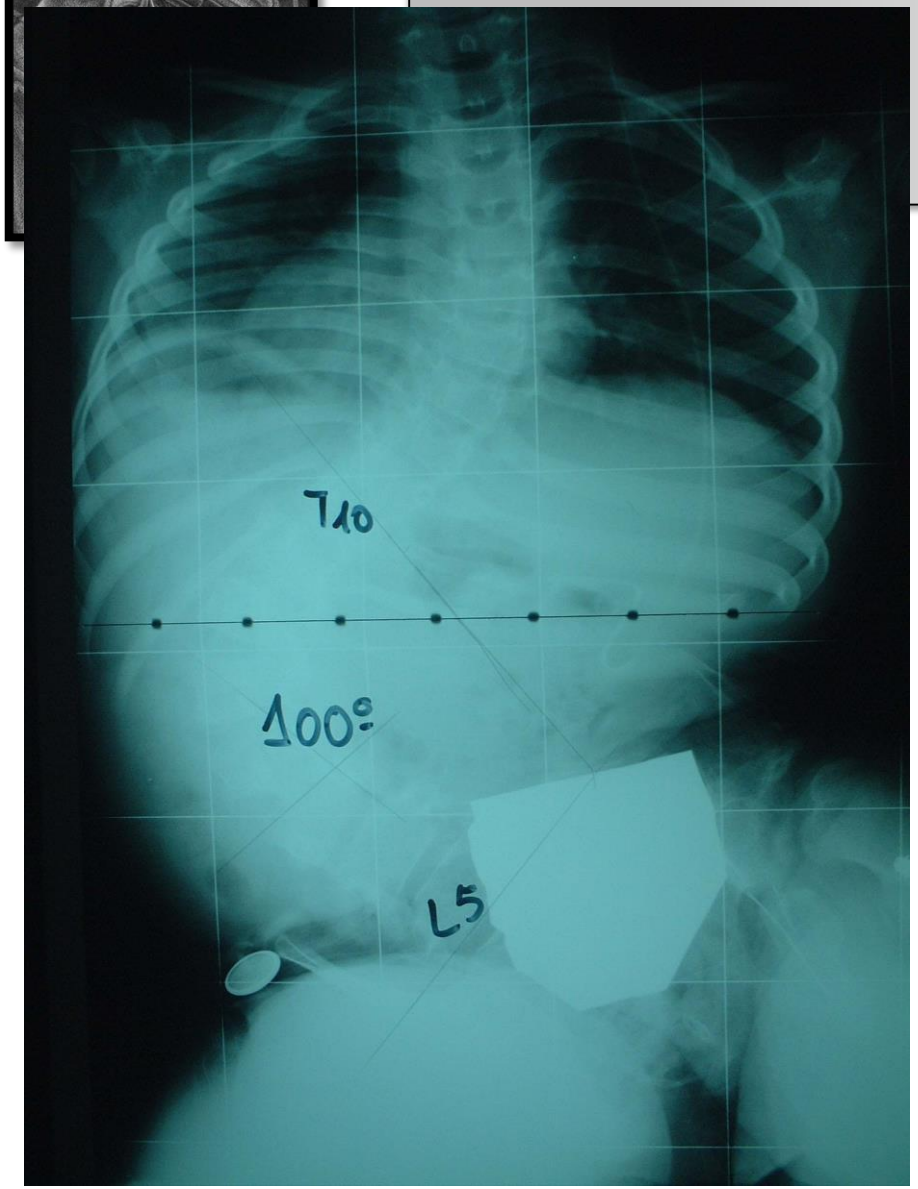
T10
100º
L5

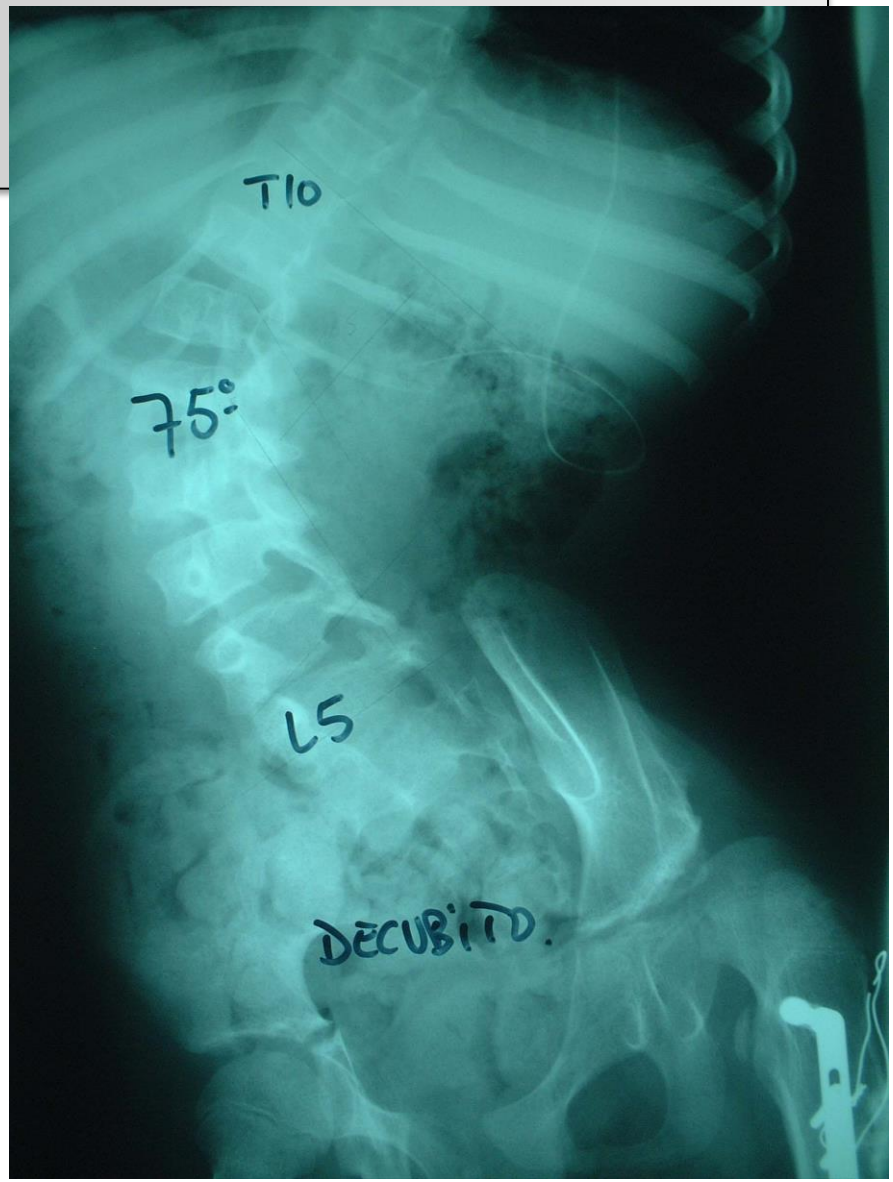
T10
75º
L5
DECUBITO.

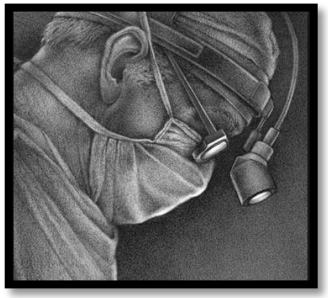

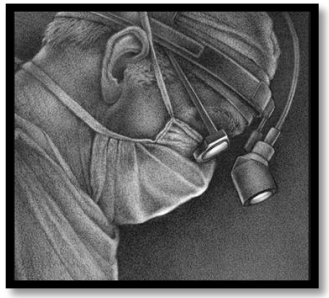

VIA ANTERIOR + POST

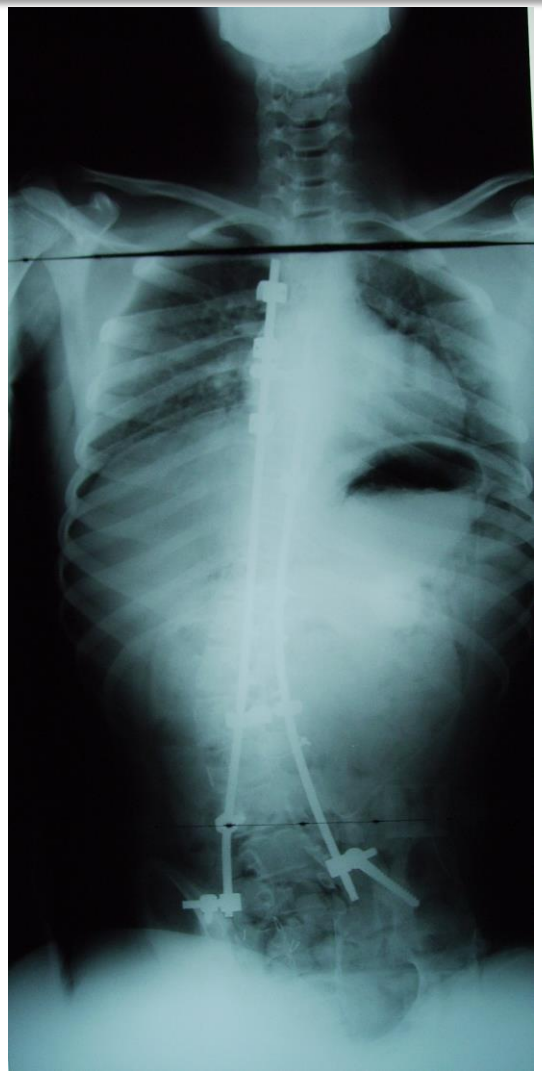

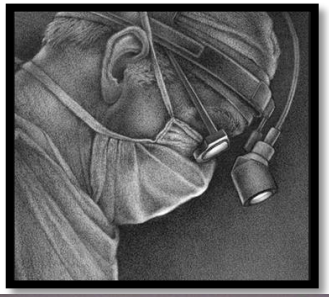

VIA ANTERIOR + POST

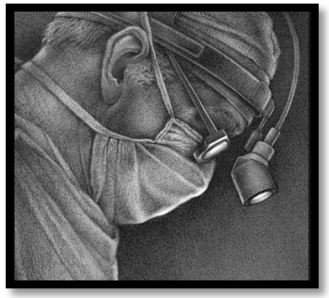

VIA ANTERIOR + POST

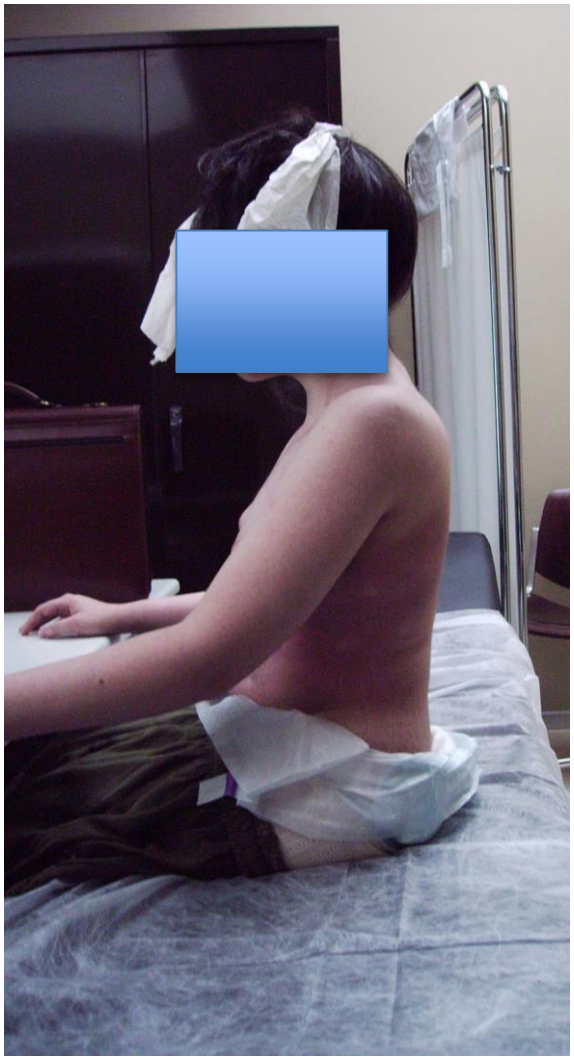

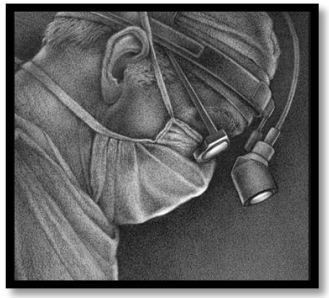

COMPLICACIONES

- Aprox 50 % de los pacientes van a sufrir complicaciones moderadas / graves
  - 60 % de ellos van a requerir cirugia para resolverlas

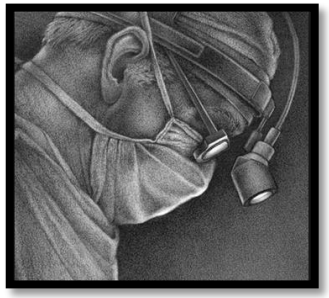

PLANIFICACION

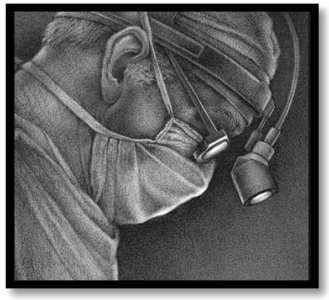

SOY TU
PULGUITA

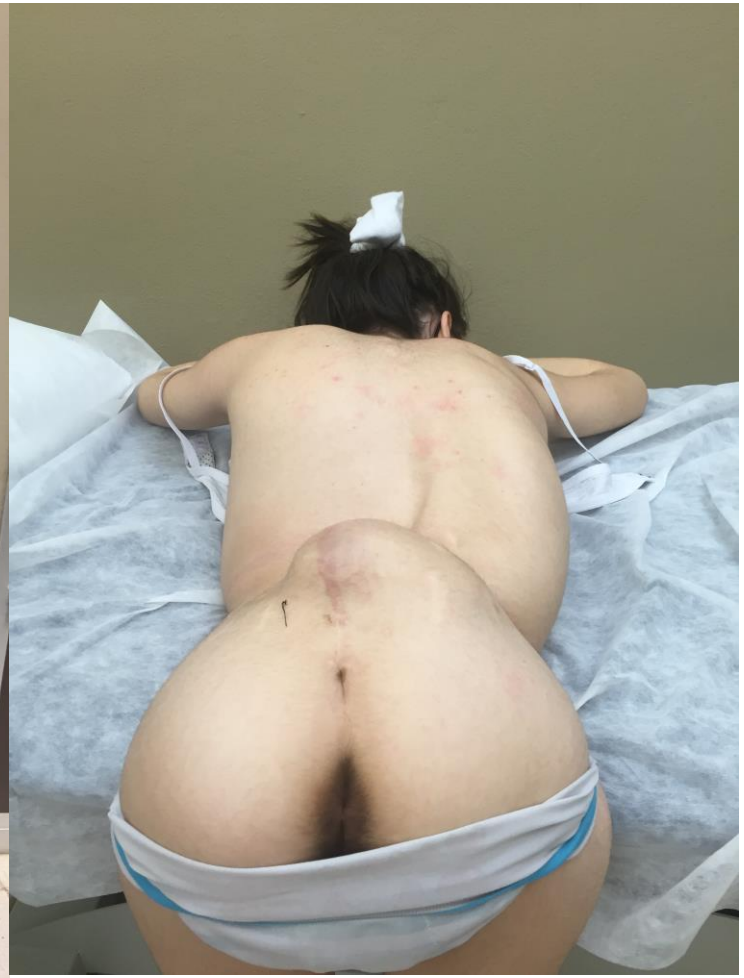

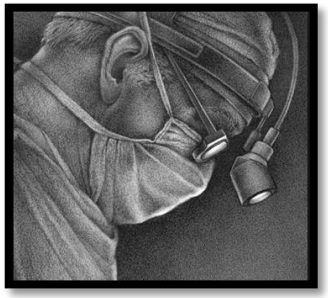

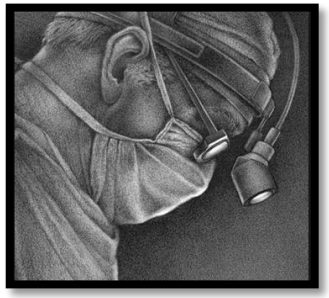

NA
D

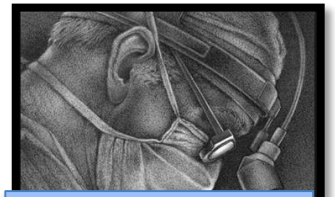

CLINICA UB
BENDING PA
Im: 5 / 6
W: 1023
L: 511
Zoom: 0.33

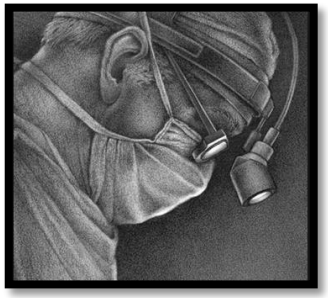

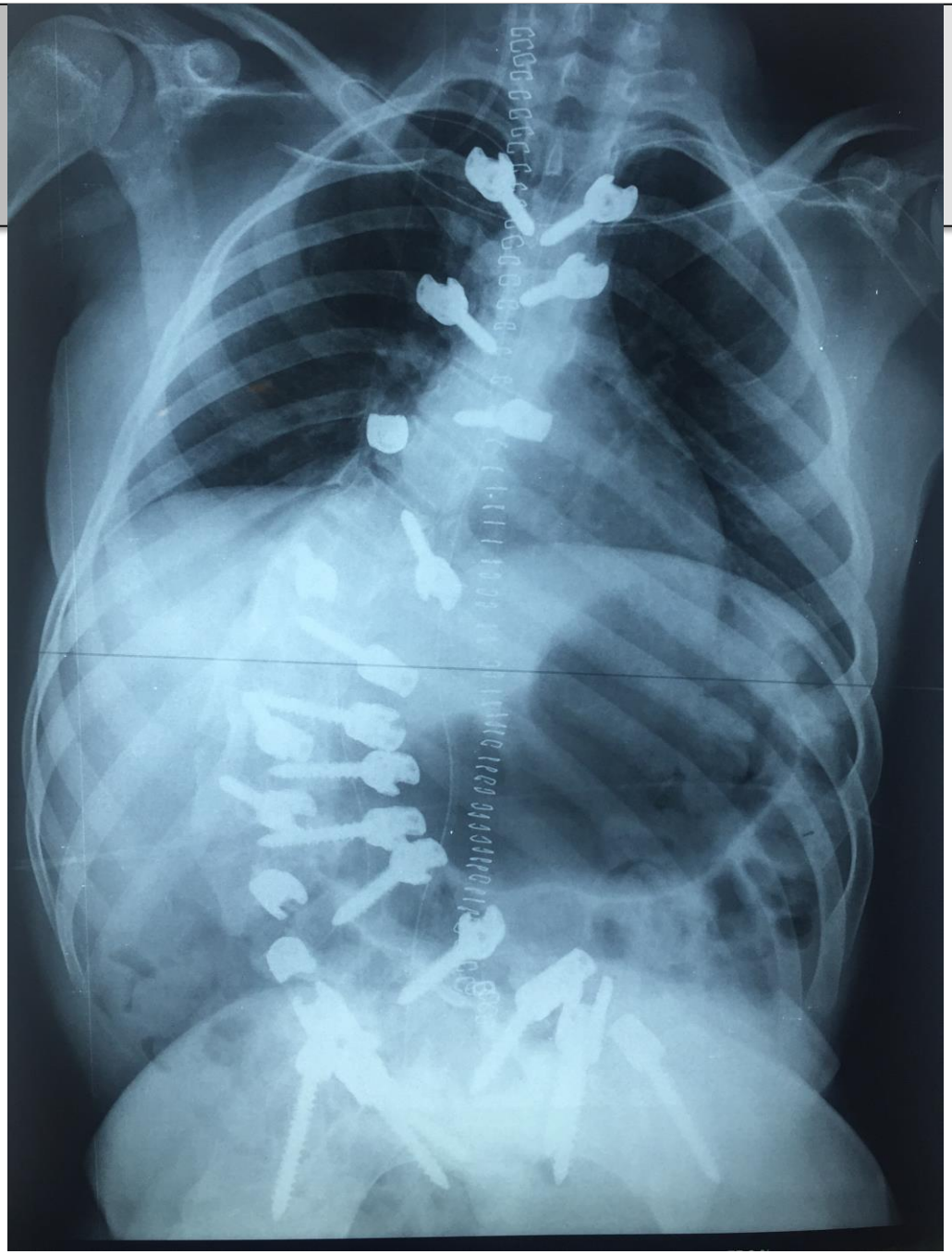

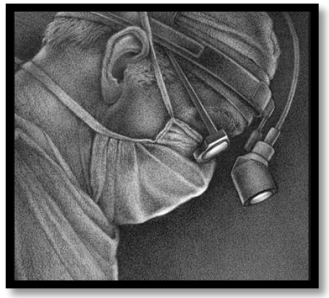

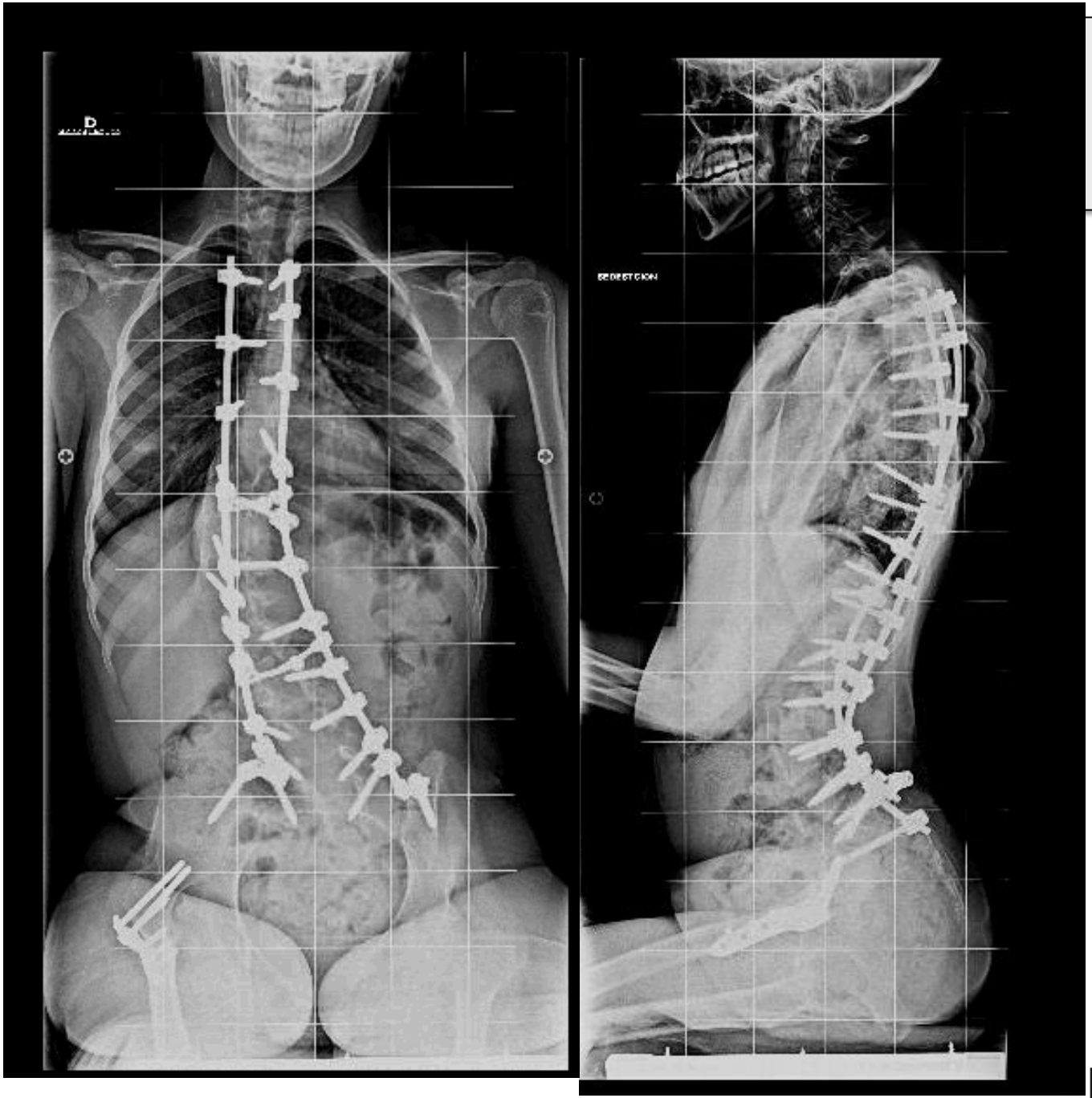
D
SEDESTACION

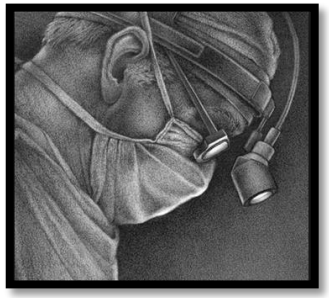

COMPLICACIONES

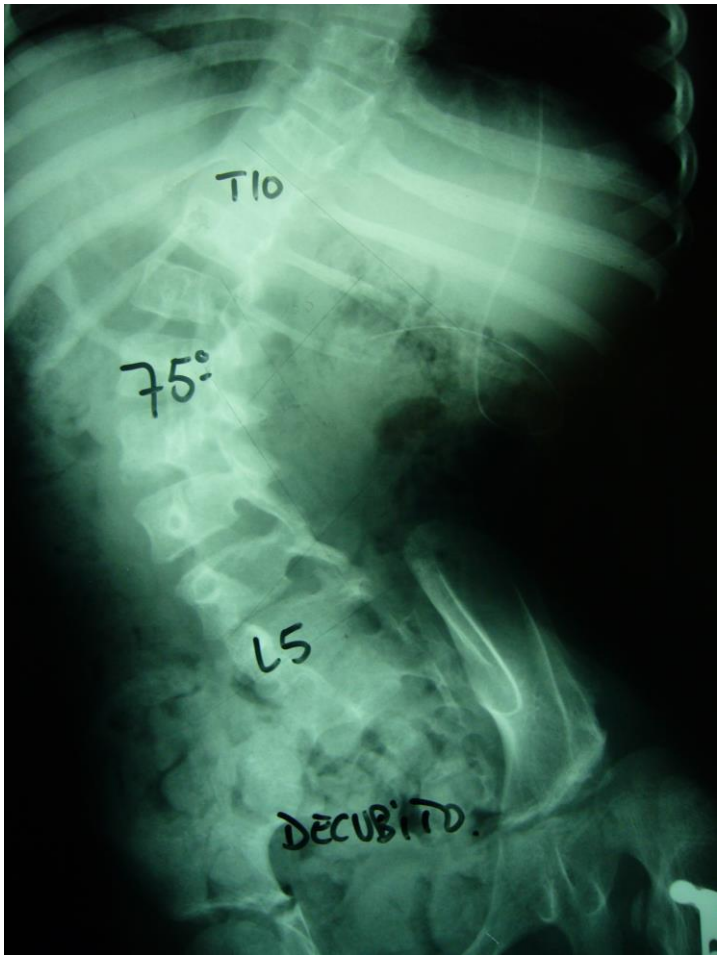

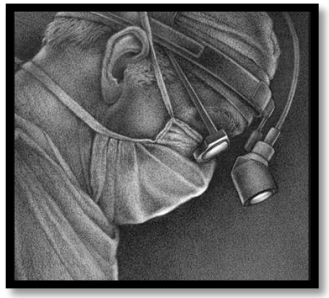

COMPLICACIONES

- Problemas cutáneos / Infección.
  - Piel cicatricial e insuficiente:
    - Uso de expansores.
    - Cura apropiada de las heridas,
    - Uso de sistemas de vacio.
    - Profilaxis ATB extendida.

Evitar la exposición de los instrumentales….
Contaminación.... Infección.

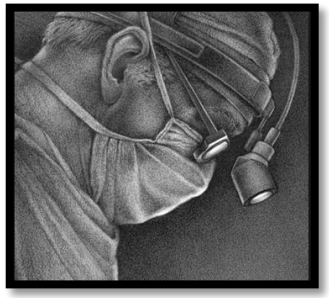

COMPLICACIONES

- Complicacione neurológicas
  - Relacionadas directamente con la cirugia.
  - Por descompensaciones de hidrocefalia...Shunt no permeables.

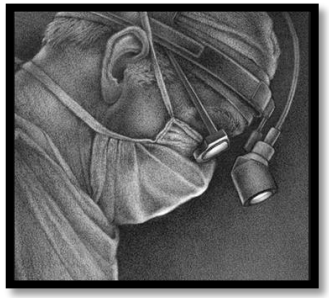

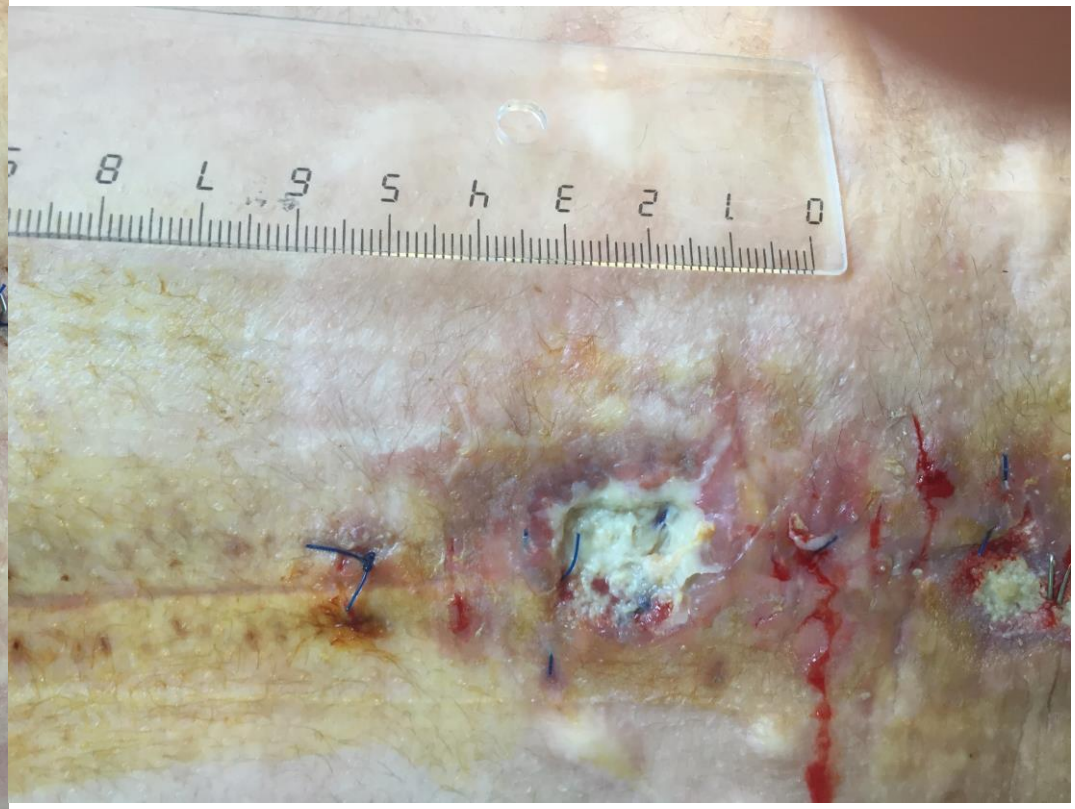

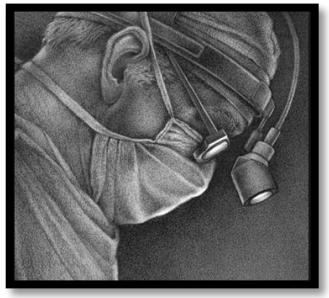

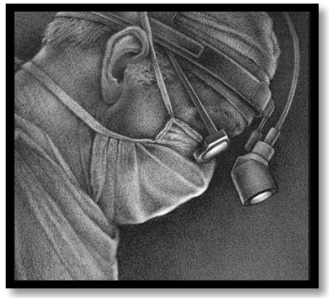

MODELADO 3D

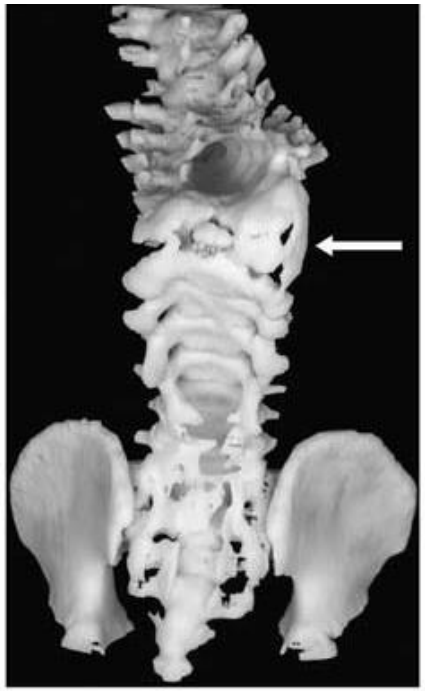

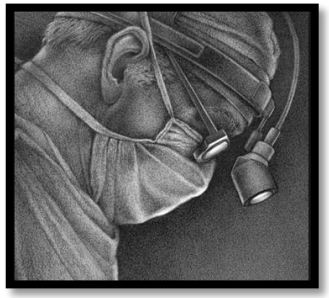

PAPEL DE LA TECNOLOGIA

- Reconstrucción 3 D con cortes de TAC.
  - Moldeado mediante impresión
  - Permite en algunas ocasiones conseguir ayuda que puede ayudar a la planificación preoperatoria/ intraoperatoria, sobre todo en lesiones complejas.
  - Medida exacta de los implantes.

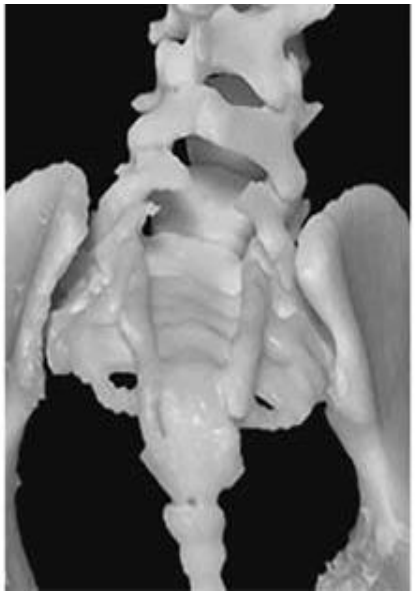

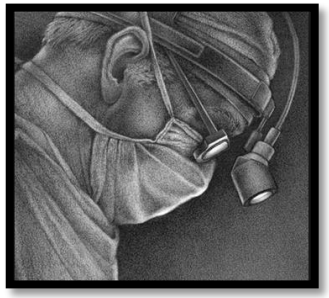

Clin Orthop Relat Res (2011) 469:1258–1264
DOI 10.1007/s11999-010-1595-y

SYMPOSIUM: MYELOMENINGOCELE

Hip and Spine Surgery is of Questionable Value in Spina Bifida

An Evidence-based Review

James G. Wright MD, MPH, FRCSC

- Escoliosis
  - No clara evidencia de su efectividad, con 40 % pseudoartrosis
- Displasia / luxación de caderas
  - Poca evidencia en relación con cirugia de recentraje… 30-45 % nuevas luxaciones
  - Lesiones por encima de L4: No de ambulantes después de la adolescencia.

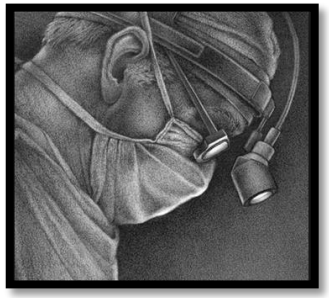

CONCLUSIONES

- Pacientes complejos.
- Planteamiento de tratamientos con exposición real de expectactivas y complicaciones.
  - Realización de consultas detalladas y pormenorizadas.
- Contar con un equipo “multidisciplinar”.

VALORACION FINAL DE RIESGO / BENEFICIO

Angel M Hidalgo
consulta@drhidalgo.es